

SOLID FREEFORM FABRICATION ASSISTING FREE FIBULA FLAP FOR THE RECONSTRUCTIVE SURGERY OF MANDIBULAR DEFECTS

Wanshan Wang¹, Wenzheng Wu^{1,2}, Tianbiao Yu¹,
Xingjun Qin³, Yadong Chen¹, David W. Rosen²

¹School of Mechanical Engineering & Automation, Northeastern University, Shenyang Liaoning 110004, P. R. China

²The George W. Woodruff School of Mechanical Engineering, Georgia Institute of Technology, Atlanta, GA 30332, U.S.A.

³Department of Oral and Maxillofacial Surgery, School of Stomatology, China Medical University, Shenyang Liaoning 110002, P. R. China

Abstract

The usage of RP models can shorten the operation time for reconstructive surgery of mandible defects using the free fibula flap technique and can improve the accuracy of mandible reconstruction. This paper reports on a case study of reconstructive surgery on a patient with a mandibular defect caused by a tumor. A customized mandible rapid prototype model was manufactured from the patient's CT data and was used to simulate the reconstructive surgery procedure. A customized titanium plate was shaped using the mandible RP model as a pattern before surgery. The usage of a mandible RP model reduced the operation time by 1.5-2.5 hours and the shape precision of the reconstructed mandible was improved. The customized titanium plate was consistent with the mandible anatomy.

Keywords: Solid Freeform Fabrication, Mandible reconstruction, Computer aided design

1 Introduction

Patients with large tumors in their lower jaw (mandible) typically require surgery for removal of the tumor (tumor resection). After tumor resection, the mandible has a range of defects, which can cause problems with their temporomandibular joints and their appearance, as well as functions such as chewing, swallowing, and speaking. Immediately following resection, the mandible must be reconstructed. In this paper, the use of rapid prototyped models of the mandible will be investigated for surgical planning and mandible fixture design.

Tumor resection typically removes additional bone and tissue surrounding the tumor (radical resection). If the region of the radical resection is small, the mandible will remain in one piece. However, for larger tumors, an osteotomy must be performed that divides the mandible into two pieces. In the former case, several options exist for the mandible reconstruction process [1]. Several researchers [2,3] utilized scaffolds for mandibular defect reconstruction [4]. In the 1970s and 1980s, some experimental and clinical studies demonstrated the possibility of replacing the resected mandibular segment in its anatomical position after immersion in liquid nitrogen to rid it of viable tumor cells [5].

In cases when an osteotomy is necessary, reconstruction usually involves a bone autograft. Most researchers and clinicians have focused on the use of one of the patient's fibulas as the source of the autograft. Hidalgo and Rekow (1995) reviewed fibula free-flap mandible reconstructions. The free flap is synonymous label used to describe the movement of tissue from one site on the body to another. "Free" implies that the tissue, along with its blood supply, is detached from the original location ("donor site") and then transferred to another location ("recipient site"). Various types of tissue may be transferred as a free flap including skin and fat, muscle, nerve, bone, or any combination of these. If the cancer or tumor involves a part of the mandible then often the fibula will be transplanted as a free flap for reconstruction of the mandible. The fibular bone has many assets that together make it an ideal choice for the reconstruction of most mandible defects [6]. The fibula was investigated as a donor site for free flap mandible reconstruction. It has the advantages of consistent shape, ample length, distant location to allow a two-team approach, and low donor-site morbidity. It can be raised with a skin island for composite-tissue reconstruction [7].

Preoperative planning of reconstructive surgery is very important to the surgical results, such as in oral and maxillofacial surgery and cranial surgery [8]. Some research on planning and simulation for cranial surgeries has been performed to aid the surgeon's understanding of the clinical situation and the surgical procedure [9,10,11]. Biomodelling of skull also has been done to aid the surgery [12]. Sailer et al. [13] have investigated the usage of stereolithographic models for preoperative diagnosis of craniofacial deformities. Rapid prototyping techniques also have been used in fabricating customized maxillo-facial prostheses and surgical templates [14,15].

In surgical planning, conventional X-ray, cephalometry, and 2D computed tomography (CT) have been the traditional methods for obtaining bone geometry shape. However, preoperative planning often is based on limited information, due to the limitation of 2D features; it is sometimes difficult to visualize the complicated osseous structures or spatial surface contour [16]. To overcome the limitations of 2D imaging, we investigated the use of 3D models for visualization and surgical planning.

2 Methods

This study describes one clinical case of a 43-year-old male patient who suffered from a mandibular tumor. The patient would undergo surgery to remove the tumor and a free fibula flap reconstruction to repair the defect. The patient's mandible was modeled virtually in 3D and physically using a rapid prototyping machine. The models were used to plan the surgery and to form a titanium plate to the proper shape to secure the reconstructed mandible. The surgery procedure is illustrated in Figure 1.

2.1 CT data acquisition

A Toshiba 64-row Spiral CT was used to scan the patient's maxilla and mandible. The CT scan parameters which were selected are shown in Table 1.

Table 1 Scanning parameters of spiral CT

Scan Speed	Pitch	Layer Thickness	Scan Voltage	Scan Current	Scan Model
27 mm/s	0.844	1 mm	120 KV	440 mA	Helical

After CT scanning, 368 layers of consecutive maxillary and mandibular CT images, at a scanning slice thickness of 1mm, were obtained and stored in the Digital Imaging and Communications in Medicine (DICOM) format. DICOM includes a file format definition and a network communications protocol. Some of the images are shown in Figure 2.

In the center and lower images of Figure 2, we can clearly observe that some regions of the mandible and teeth are missing due to the tumor growth. That is the part which needs to be removed. The patient also needs consideration for tooth growth after the operation, although that aspect is not covered in this paper. Figure 3 is a preoperative CT image of the patient. The mandible has an obvious hole as the result of the large tumor.

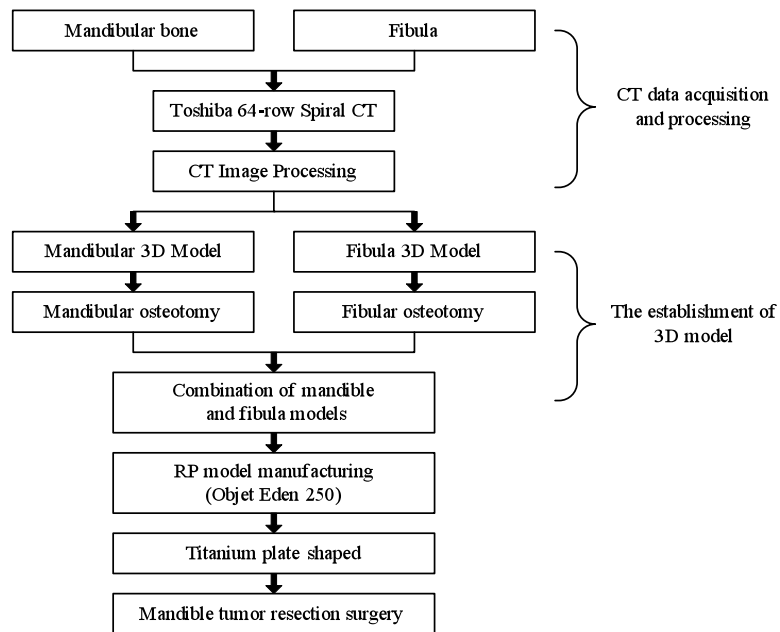


Figure 1 The surgery procedures

According to the mandible CT images, the surgeon could understand most of the affected parts of the mandible. But they are just 2D images that do not give a full sense of the three dimensional layout of the tumor and mandible. Furthermore, they could not fabricate accurately the customized titanium plate that is needed to secure the reconstructed mandible. As a result, we needed to construct a 3D model of the mandible. CT images of the patient's fibula were

collected also, as shown in Figure 4.

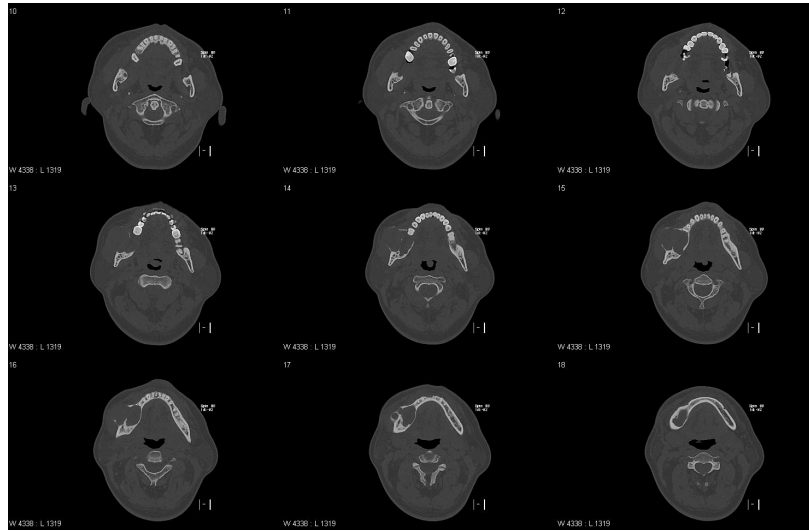


Figure 2 Mandible CT images

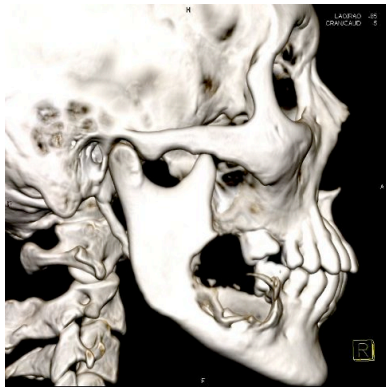

Figure 3 Mandible 3D CT image before surgery

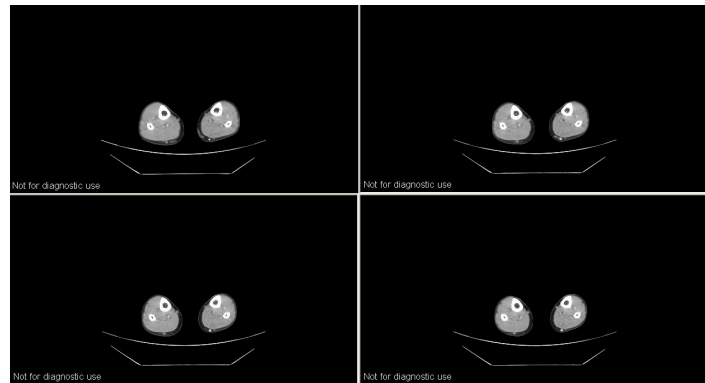


Figure 4 Fibula CT images

2.2 Establishment and optimization of 3D model

After the CT data acquisition, the original CT images were loaded into Mimics software (Materialise, Inc., Leuven, Belgium). After manipulating bone threshold values, the contour lines of every layer were extracted. Every image was processed by dividing edges, selective editing, filling holes, and removing redundant regions, as needed. After that, the 3D geometric models of the maxilla and mandible were obtained as shown in Figure 5. A similar procedure was followed for the fibula; its 3D model is shown in Figure 7.

The healthy side of the mandible was selected as a reference to reconstruct the damaged side.

A complete 3D model of the mandible was constructed by mirroring the healthy side. This model was used for surgical planning.

For surgery, the surgeons decided that 2 cm of bone was to be removed around the tumor. This will result in removing approximately 8 cm of the mandible. To repair that defect, three fibula sections will be used in the free fibula flap technique. The fibula from the same side of the body as the tumor is selected for harvesting. The three fibula sections are shown at the top of Figure 7. After shaping the fibula sections, the mandibular repair can be constructed using those sections, as shown in Figure 6.

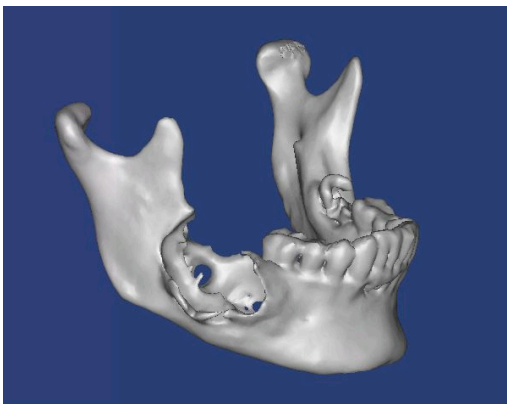


Figure 5 Original mandible 3D model

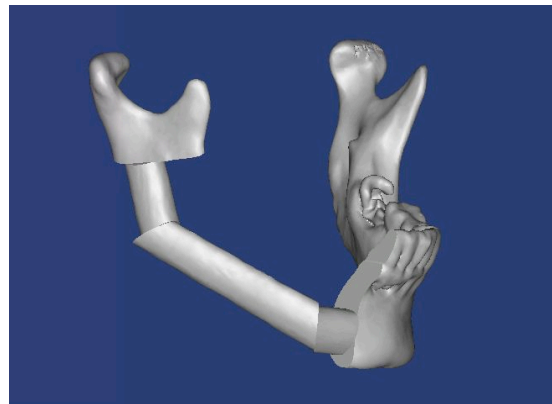


Figure 6 3D model of reconstructed mandible.




Figure 7 Fibula 3D model

After the virtual mandible reconstruction was completed, an STL file was output from Mimics so that it could be input to Magics (Materialise). In Magics, the STL file was edited and simplified so that it was only one shell and contained a reduced number of triangles.

2.3 RP model manufacture

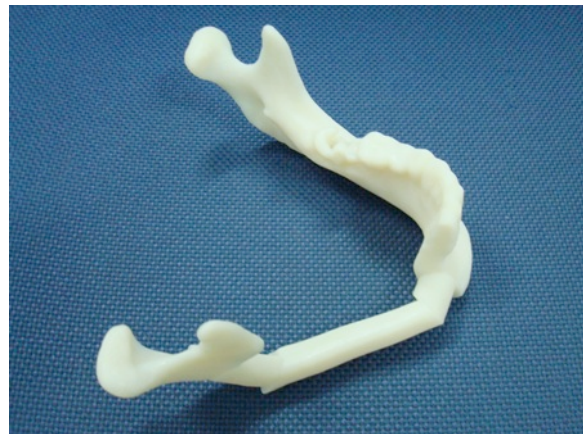Two RP models of the mandible were built on an Objet Eden 250 machine, one is the

original mandible with the tumor and the other is the reconstructed mandible. Additionally, a model of the fibula was built. The STL files from Magics were input into the Objet Studio software to set up the builds. For the model of the reconstructed mandible, the fabrication time was almost 9 hours. Other build data are shown in Table 2. The RP model is shown in Figure 8. A model of the original mandible was constructed to allow the surgeons to better visualize the 3D geometry and is shown in Figure 9.

Table 2 Actual mandible RP model material consumption

	Model Resin	Support Resin
Material	Vero White	Full Cure 705 Support
Material Mass	161 g	149 g
Total time	8 hours 50 minutes	

The fibula RP model provided the surgeons with an opportunity to plan aspects of the reconstruction procedure. The doctor could mark on the RP model where to make cuts that form the three pieces that will be used to fill the mandible defect. The model was taken into the operating room as a reference and helped to short the operation time. Figure 10 shows the fibula RP model.



(a)

(b)

Figure 8 Objet model of the reconstructed mandible

3 Result

In free fibula flap reconstructions, a means of securing the mandible and fibula sections is needed. A custom fabricated titanium plate, and titanium nails, was chosen as the fixturing method for this reconstruction. Titanium has good properties for this application, such as high excellent biocompatibility, high specific strength, low density, and good corrosion and oxidation

resistance. The RP model of the reconstructed mandible, Figure 8, was used as a pattern when the titanium plate was formed. In this manner, the surgeons can assure a good fit between the plate and the patient's mandible before surgery by test-fitting the plate to the mandible model. The customized titanium plate is shown in Figure 11.

The customized titanium plate design achieves a good balance between mechanical and biological considerations. The plate shape conforms to the patient's mandible. The plate is thick enough to provide the strength and stiffness needed to fix the mandible until the bone grafts and soft tissues heal. At the same time it is thin enough to avoid extensive intrusion into soft tissues and to avoid weighing too much for the patient's jaw.

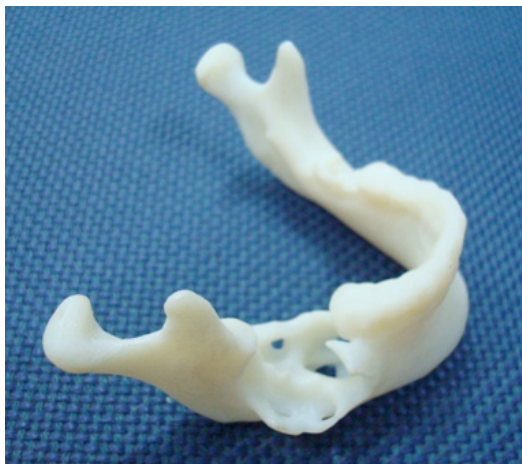

Figure 9 Original mandible RP model

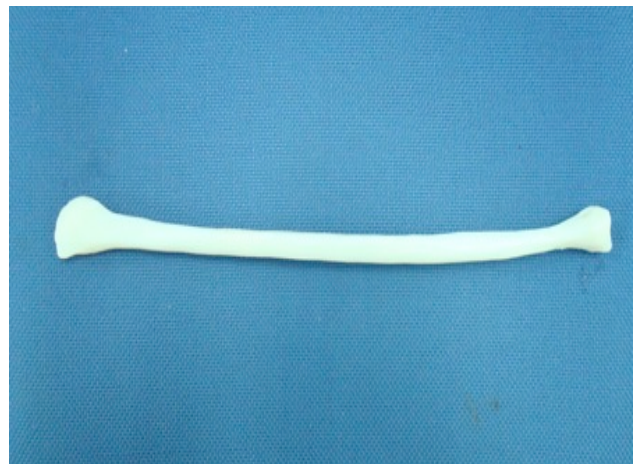

Figure 10 Original fibula RP model

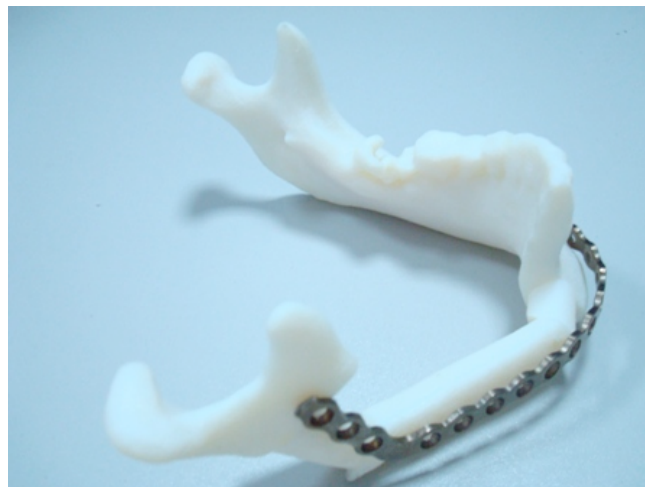

Figure 11 Customized Titanium plate and reconstruction mandible RP model

In typical free fibula flap surgeries, it takes 3-4 hours to cut the fibular bone and shape it for mandible reconstruction. In this case study it only took 1.5 hour to cut and shape the fibular bone

due to the usage of the RP models. Compared to the traditional methods of preoperative planning, the doctor could save 1.5-2.5 hours of operation time by using RP models as planning aids and as a guide for forming the titanium plate. As a result, the use of RP models in mandibular reconstruction saved a significant amount of operation time by simplifying some of the steps of the operation.

The soft tissue surrounding the mandible (e.g., muscle), as well as the skin, requires approximately two weeks to heal. It will take 3-6 months for the complete recovery of mandibular bone.

4 Conclusion

In this project, RP models were used to aid surgery planning and fixture design for reconstructing the mandible after radical resection of a tumor. The patient's CT data were used to establish 3D mandible models and a model of the fibula, which is used for a bone autograft. As part of the mandible reconstruction process, a titanium plate was fabricated for use as a fixture for the mandible sections and the fibula bone graft segments. Additionally, the RP models of the reconstructed mandible were used as a pattern to form the titanium plate into the correct shape for the specific patient.

The RP model of the mandible with the tumor helped the surgeon to be certain of the tumor's location so that he could plan the resection more carefully. It also could help the surgeon to have an intuitive 3D understanding of the affected part. The doctor could mark on the RP model which part will be cut. The model was taken into the operation room as an osteotomy guide and also was helpful in reducing the operation time by 1.5-2.5 hours, compared to typical mandible osteotomies and reconstructions.

In conclusion, the RP technology has the possibility to reduce the operation time of free fibula flap for surgical reconstruction of mandibular defects, and increase surgical precision over surgeries performed without the aid of RP models.

References

- [1] Robey, A.B., Spann, M.L., McAuliff, T.M., Meza, J.L., Hollins, R.R., Johnson, P.J. (2008), "Comparison of Miniplates and Reconstruction Plates in Fibular Flap Reconstruction of the Mandible", *Plastic and Reconstructive Surgery*, Vol. 122, pp. 1733-8.
- [2] Schuckert, K.H., Jopp, S., Teoh, S.H. (2009), "Mandibular Defect Reconstruction Using Three - Dimensional Polycaprolactone Scaffold in Combination with Platelet-Rich Plasma and Recombinant Human Bone Morphogenetic Protein-2: De Novo Synthesis of Bone in a Single Case", *Tissue Engineering Part A*, Vol. 15(3), pp. 493-499.
- [3] Ploder, O., Kohnke, R., Klug, C., Kolk, A., Winsauer, H. (2009), "Three-Dimensional Measurement of the Mandible after Mandibular Midline Distraction Using a Cemented and

Screw-Fixated Tooth-Borne Appliance: A Clinical Study”, *Journal of Oral and Maxillofacial Surgery*, Vol. 67, pp. 582-588.

- [4] Santamaria, E., Morales, C., Taylor, J.A., Hay, A., Ortiz-Monasterio, F. (2008), “Mandibular Microsurgical Reconstruction in Patients with Hemifacial Microsomia”, *Plastic and Reconstructive Surgery*, Vol. 122, pp. 1839-1849.
- [5] Weaver, A.W., Smith, D.B. (1973), “Frozen autogenous mandibular stent-graft for immediate reconstruction in oral cancer surgery”, *Am J Surg*, Vol. 126, pp. 505- 6.
- [6] Hidalgo, D.A. and Rekow, A. (1995), “A review of 60 consecutive fibula free-flap mandible reconstructions”, *Plastic and Reconstructive Surgery*, Vol. 96 No. 3 pp. 585-596.
- [7] Hidalgo, D.A. (1989), “Fibula free flap: a new method of mandible reconstruction”, *Plastic and Reconstructive Surgery*, Vol. 84 No. 1, pp. 71-79.
- [8] Wu, W.Z., Zhang, Y., Li, H., Wang, W.S. (2009), “Fabrication of Repairing Skull Bone Defects Based on the Rapid Prototyping”, *Journal of Bioactive and Compatible Polymers*, Vol. 24 (1 Suppl), pp. 125-136.
- [9] Anderl, H., Zur, Nedden, D., Muhlbauer, W., Twerdy, K., Zanon, E., Wicke, K., and Knapp, R. (1994), “CT-guided stereolithography as a new tool in craniofacial surgery”, *British Journal of Plastic Surgery*, Vol. 47 No. 1, pp. 60-4.
- [10] Abe, M., Tabuchi, K., Goto, M. and Uchino, A. (1998), “Model-based surgical planning and simulation of cranial base surgery”, *Neurologia Medico-Chirurgica*, Vol. 38 No.11, pp.746-50 (Discussion750-1).
- [11] Muller, A., Krishnan, K.G., Uhl, E. and Mast, G. (2003), “The application of rapid prototyping techniques in cranial reconstruction and preoperative planning in neurosurgery”, *Journal of Craniofacial Surgery*, Vol. 14 No. 6, pp. 899-914.
- [12] D’Urso, P.S., Anderson, R.L., Weidmann, M.J., Redmond, M.J., Hall, B.I., Earwaker, W.J., Thompson, R.G. and Effeney, D.J. (1999), “Biomodelling of skull base tumours”, *Journal of Clinical Neuroscience*, Vol. 6 No.1, pp. 31-5.
- [13] Sailer, H.F., Haers, P.E., Zollikofer, C.P., Warnke, T., Carls, F.R. and Stucki, P. (1998), “The value of stereolithographic models for preoperative diagnosis of craniofacial deformities and planning of surgical corrections”, *International Journal of Oral andMaxillofacial Surgery*, Vol. 27 No. 5, pp. 327-33.
- [14] Singare, S., Liu, Y.X., Li, D.C., Lu, B.H., He, S.H. and Li, G. (2006), “Fabrication of customised maxillo-facial prosthesis using computer-aided design and rapid prototyping techniques”, *Rapid Prototyping Journal*, Vol. 12 No. 4, pp. 206-13.
- [15] Potamianos, P., Amis, A.A., Forester, A.J., McGurk, M. and Bircher, M. (1998), “Rapid prototyping for orthopaedic surgery”, *Proceedings of the Institution of Mechanical Engineers. Part H, Journal of Engineering in Medicine*, Vol. 212 No. 5, pp. 383-93.
- [16] Lee, M.Y., Chang, C.C., Lin, C.C., Lo, L.J. and Chen, Y.R. (2002), “Custom implant design for patient with cranial defect”, *IEEE Engineering in Medicine and Biology*, Vol. 21 No. 2, pp. 38-44.